SCINDEKS Serbian Citation Index
J Med Biochem 2026; 45 (1) DOI: 10.5937/jomb0-61972

UDK 577.1 : 61 **ISSN 1452-8258**

J Med Biochem 45: 23–32, 2026

Review paper
Revijski rad

ENDOCRINE EFFECT OF GHRELIN ON HISTOLOGICAL, HORMONAL AND MORPHOMETRIC PARAMETERS OF THE PITUITARY GLAND AND THE POSSIBILITY OF ITS CLINICAL APPLICATION

ENDOKRINI EFEKTI GRELINA NA HISTOLOŠKE, HORMONSKE I MORFOMETRIJSKE PARAMETRE HIPOFIZE I MOGUĆNOST NJEGOVE KLINIČKE PRIMENE

Jovana Čukuranović Kokoris[1], Verica Milošević[1], Darko Stevanović[2]

[1]University of Niš, Faculty of Medicine, Department of Anatomy, Niš, Serbia
[2]Center for Life Science, Beth Israel Deaconess Medical Centre, Harvard Medical School, 3 Blackfan Circle, Boston, MA 02115, USA

Summary

Background: Ghrelin, a brain-intestinal hormone, is a growth hormone (GH) secretagogue. Because it regulates appetite and is secreted most prominently before meals, it is often described as a »hunger hormone«. It consists of 28 amino acids. Given the connection between nutritional status and energy metabolism, it suggests that disorders in these areas can lead to anorexia, especially during aging. This review article aims to demonstrate ghrelin's influence on the histological, hormonal, and stereological characteristics of pituitary cells, as well as its potential clinical applications.
Methods: To write this review, we performed an electronic literature search through Google Scholar and PubMed databases with the terms ghrelin, structure, pituitary cells, metabolism, and aging, with reference to the authors and co-authors of published works related to this topic, as well as the option »related articles«, which were associated with the content of this publication.
Results: The topic of this review article relates to the structure, morphometric and hormonal characteristics of adrenocorticotropic (ACTH), somatotropic (GH), and gonadotropic (FSH and LH) pituitary cells in control and ghrelin-treated rats.
Conclusions: This review showed that central administration of nanomolar doses of ghrelin in rats modulates the immunohistomorphometric and hormonal characteristics of pituitary hormone-producing cells. The changes are particularly significant in the volume of corticotropes, somatotropes, and luteinising hormone (LH)- producing cells, their volume density, and the levels of hormones they secrete, compared with the control group.

Keywords: ghrelin, pituitary cells, hormonal status, morphometry, clinical application

Kratak sadržaj

Uvod: Grelin, moždano-crevni hormon, je sekretagog hormona rasta (GH), a pošto reguliše apetit i najviše se luči pre obroka, opisuje se kao »hormon gladi«. Sastoji se od 28 aminokiselina. S obzirom na vezu između nutritivnog statusa i energetskog metabolizma, sugeriše se da poremećaji u ovim oblastima mogu dovesti do anoreksije, posebno tokom starenja. Cilj ovog preglednog članka je da pokaže uticaj grelina na histološke, hormonske i stereološke karakteristike ćelija hipofize, kao i mogućnost njegove kliničke primene.
Metode: Da bismo napisali ovaj pregled, izvršili smo elektronsku pretragu literature putem baza podataka »Google Scholar PubMed« i sa terminima grelin, struktura, ćelije hipofize, metabolizam, starenje sa pozivanjem na autore i koautore objavljenih radova vezanih za ovu temu, kao i opciju »povezani članci«, koji su bili povezani sa sadržajem ove publikacije.
Rezultati: Tema ovog preglednog članka odnosi se na strukturu, morfometrijske i hormonske karakteristike adrenokortikotropnih (ACTH), somatotropnih (GH), gonadotropnih (FSH i LH) ćelija hipofize kod kontrolnih i pacova tretiranih grelinom.
Zaključak: Ovaj pregled je pokazao da centralna primena nanomolarnih doza grelina pacovima ima modulatornu ulogu na imunohistomorfometrijske i hormonske karakteristike ćelija hipofize koje proizvode hormone. Promene su posebno značajne u zapremini kortikotropa, somatotropa i ćelija koje proizvode luteinizirajući hormon (LH), njihovoj zapreminskoj gustini i nivoima hormona koje luče u poređenju sa kontrolnom grupom.

Ključne reči: grelin, ćelije hipofize, hormonski status, morfometrija, klinička primena

Address for correspondence:
Jovana Čukuranović Kokoris, PhD
Department of Anatomy, Faculty of Medicine, University of Niš
81 Dr Zorana Đinđića Boulevard, 18000 Niš, Serbia
Phone: +381 64 529 55 76
e-mail: jovana.cukuranovic.kokoris@medfak.ni.ac.rs

Introduction

The hormone ghrelin is an orexigenic hormone that was purified from the stomach more than 20 years ago and described by Koima et al. (1). This hormone stimulates appetite (2), promotes gastric acid secretion and motility, facilitates lipogenesis, inhibits lipid oxidation, utilises carbohydrates as a fuel source, and conserves fat (3). It is secreted before meals, which is why it is called the »hunger hormone« (4). The human ghrelin gene is located on chromosome 3 (3p25-26) (5), spans six exons, and is approximately 7.2 kb in length. To form the mature mRNA that is translated into pre-proghrelin, which consists of 117 amino acids, the ghrelin gene undergoes transcription (6). In the endoplasmic reticulum, pre-proghrelin is cleaved by proteases to form proghrelin, which contains 94 amino acids (6). In the subsequent biochemical process, proghrelin is converted to mature ghrelin (7), which is then converted to des-acyl ghrelin and acyl ghrelin by ghrelin-O-acyltransferase (8). Mature ghrelin contains 28 amino acids (7). It is assumed that acylated ghrelin (AG) is converted to obestatin (9). More than 90% of desacyl ghrelin and less than 10% of AC circulate in the circulation (10). It is known that the acyl group of ghrelin is responsible for binding ghrelin to the growth hormone secretagogue receptor (GHS-R) (1). The primary function of AG is the secretion of growth hormone (GH), and the function of diacylglycerol (DAG) is lipogenesis (11). Ghrelin has multiple functions, including physiological, biological and pathological roles in vertebrates (12). In addition to humans, it has been identified in many animal species, including frogs, fish, chickens, pigs, mice, and rats (13). Human ghrelin differs from rat ghrelin by only two amino acids at positions 11 and 12 (1, 14). It has been observed that after surgical removal of the gastric mucosa, C-ghrelin concentration decreases in both humans (10) and rats (approximately 80%) (15). This hormone is widely distributed across various tissues, including the hypothalamus, pituitary gland, kidneys, heart, intestines, pancreas, adrenal gland, and testes (9), indicating its importance in both endocrine and paracrine roles (16). Ghrelin is involved in a wide range of biological processes; it is crucial for memory, learning, sleep, cognition, and the senses of smell and taste (2), as well as the maintenance of energy and bone homeostasis. It has anti-atrophic and cardioprotective functions (17). Its importance in stimulating skeletal muscle regeneration after injury has been observed (2). As a »hunger hormone«, ghrelin stimulates appetite and food intake after binding to receptors and thereby activating orexigenic neurons in the arcuate nucleus of the hypothalamus (17). Numerous studies have

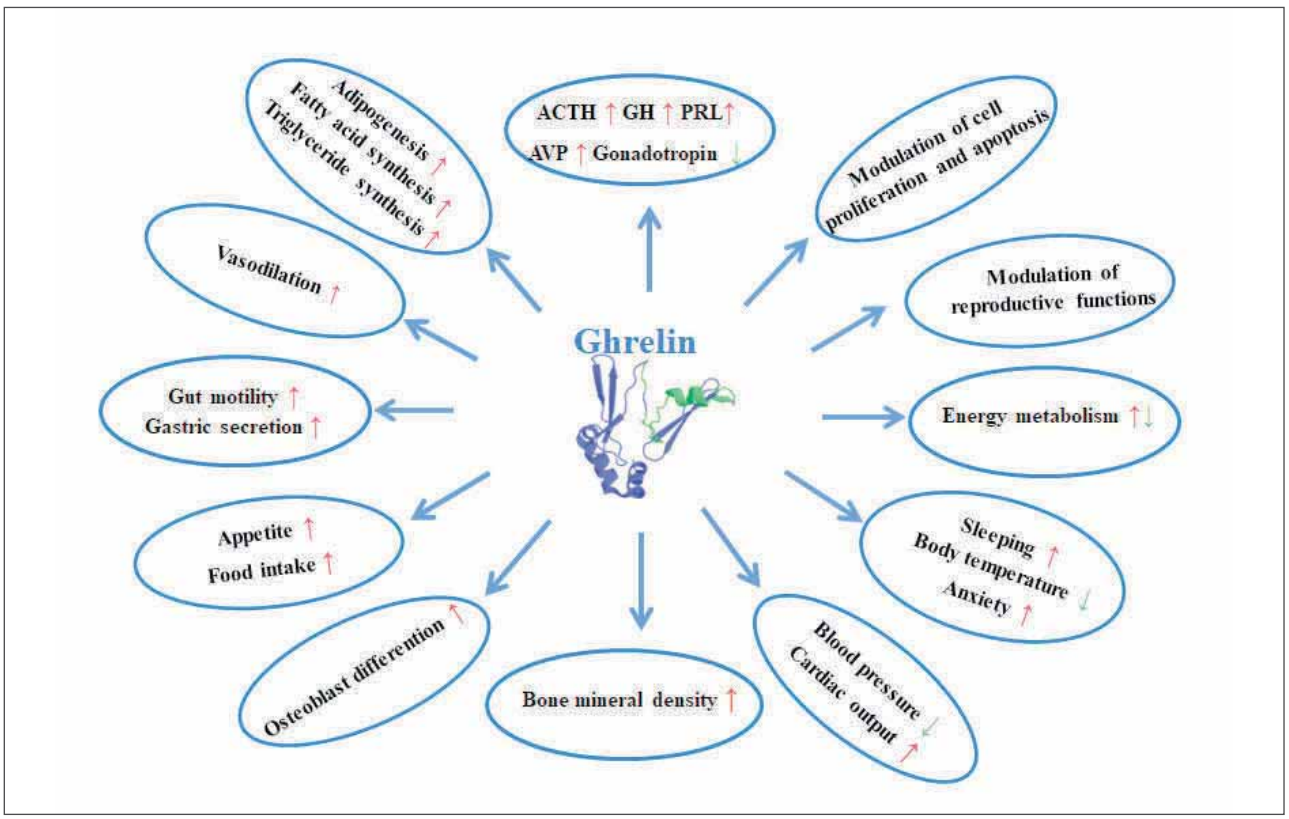

Figure 1 The various physiological functions of ghrelin in the body: ↑increase, ↓decrease; ACTH – adrenocorticotropic hormone; GH – growth hormone; PRL – prolactin; AVP – arginine-vasopressin.

shown that aging is associated with a decrease in appetite, leading to a corresponding decline in energy intake of approximately 1% per year (18, 19). During this process, metabolic pathways are disrupted, leading to pathological weight loss and malnutrition (18). The physiological functions of ghrelin are shown in *Figure 1*.

Research by Landi et al. (20) showed that as people age, ghrelin concentrations decrease, indicating an adverse effect on appetite and food intake, which should be an additional incentive for scientists to investigate further its potential for safe clinical application in »anorexia of aging«. Research has shown that ghrelin has therapeutic implications, as it induces autophagy, and its inhibitory effects protect the body from unwanted inflammation (21).

Histological characteristics of pituitary cells after ghrelin treatment

Adrenocorticotropic (ACTH) cells in the control pituitary of male rats are mainly found in small groups near the capillaries. They are irregularly shaped, mostly stellate, and are located in the central part of the pars distalis. These cells are intensely stained, with clearly visible nuclei surrounded by immunopositive, granular cytoplasm (*Figure 2A*) (22, 23). In male cadavers, immunohistochemically positive ACTH cells

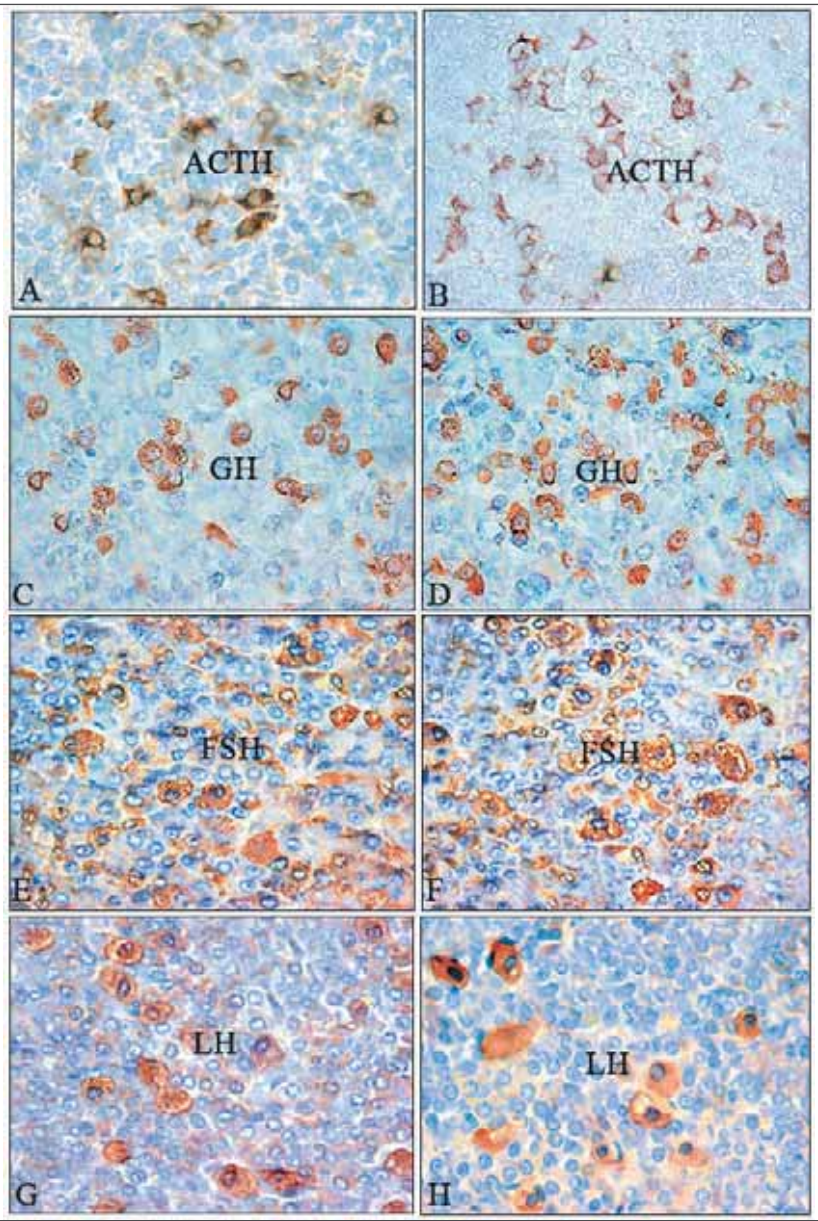

Figure 2 Representative micrographs of immunopositive cells in the pars distalis of the pituitary gland from control: A, C, E, G (ACTH, GH, FSH, LH respectively); from ghrelin treated rats: B, D, F, H (ACTH, GH, FSH, LH respectively). ACTH-corticotropic cells, GH-somatotropic cells, follicle-stimulating-FSH-producing cells, luteinizing-LH-producing cells. Peroxidase–antiperoxidase (PAP) method.

are darkly stained, with voluminous cytoplasm and an eccentric nucleus, and they typically appear star-shaped, oval, or polygonal (24, 25). In treated animals with ghrelin, neither the localisation nor the shape of ACTH-immunoreactive cells was altered compared with the control (*Figure 2B*). Secretory granules in these animals are more numerous, darker in colour than in controls, and distributed along the plasma membrane (*Figure 2B*) (22).

Histological analysis of ACTH-immunopositive cells in high-fed (HF) and food-restricted (FR) rats revealed no significant changes in shape or position. Still, they appeared darker and smaller than in normal-fed (NF) controls. Ghrelin treatment did not alter the shape of ACTH cells in HF and FR rats compared to their respective controls; however, they became more lightly stained and larger, with granules distributed around the periphery of the cytoplasm (26).

In control male rats, somatotropic (GH) cells are immunocytochemically positive for GH and are ovoidal or pyramidal, with a centrally located spherical nucleus. Intensely stained GH cells were usually located along the sinusoid (*Figure 2C*) (27, 28). Pituitary immunoreactive GH cells of the adenohypophysis in a male cadaver were polygonal with a nucleus that is euchromatic and eccentrically placed (29, 30). In rats treated with ghrelin, immunopositive GH cells were more numerous and larger, and their localisation and shape were generally not significantly altered compared to controls. Darker, more numerous, and smaller secretory granules were distributed mainly at the periphery of the cytoplasm (*Figure 2D*) (27).

Thyrotropic (TSH) cells in adult control rats were found in the distal part of the pituitary gland, mostly singly or localised in small groups, and immunoreactivity was not found in the cytoplasm. In rats administered ghrelin centrally, TSH cells were often degranulated in the peripheral cytoplasm, reduced in size by 13%, and the relative volume density of these cells per unit volume of the pituitary was reduced by 18% compared to controls (31).

Gonadotropic cells (cells that produce follicle-stimulating hormone-FSH and luteinising hormone-LH) were intensely stained (*Figure 2E, G*). These cells in adult male rats were oval in shape, in contact with capillaries, and distributed singly or in groups in the distal part of the pituitary gland. In both cell types, the nucleus was eccentrically positioned (*Figure 2E, G*) (32). In cadaveric men, LH cells are most often polygonal or oval, with numerous granules in the darkly stained cytoplasm (33, 34). In ghrelin-treated rats, histological analysis revealed that FSH and LH cells did not exhibit significant changes in shape or distribution within the rat pituitary. Both cell types were slightly lighter in colour than controls (*Figure 2F, H*) (32).

Hormonal status of pituitary cells after ghrelin treatment

Previous studies have shown that ghrelin, in addition to its strong influence on growth hormone release, plays a crucial role in regulating prolactin (PRL), adrenocorticotropic hormone (ACTH), and cortisol secretion (2, 16, 17). Studies by Yanagi et al. (21) have shown that ghrelin is involved in stress regulation, and Stevanović et al. (22) found that nanomolar doses of ghrelin significantly increased blood ACTH and corticosterone concentrations (*Figure 3A, C*) by 62% and 66%, respectively, compared to control rats. In rats fed different diets, it was

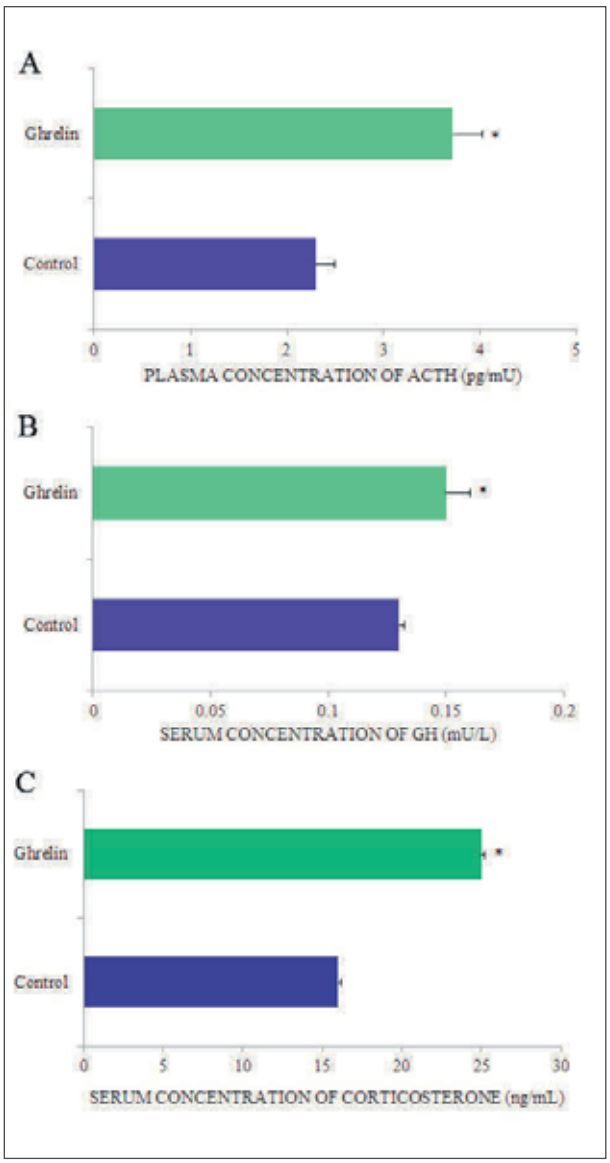

Figure 3 Graphic representation of the concentration of hormone in the blood of control and ghrelin-treated adult rats

All values are expressed as means ± S.D.; *$p<0.05$ vs. control; n=10.

shown that ACTH and corticosterone levels increased in NF and FR rats, whereas in HF rats, these parameters did not change significantly (26).

Ghrelin in vivo has a stimulatory effect on the hypothalamic-pituitary-adrenal (HPA) axis (35) and on ACTH release, due to the synergistic action of corticotropin-releasing hormone (CRH) and arginine vasopressin (AVP) from the hypothalamus (36). Centrally administered ghrelin stimulates the HPA axis by releasing both CRH and AVP, whereas systemic ghrelin does not (37). Increased plasma ghrelin concentration increases serum cortisol levels, independent of increases in central ACTH (38), as the adrenal gland contains ghrelin receptors (39).

Growth hormone (GH) release is regulated by hypothalamic ghrelin and pituitary ghrelin, which, in this case, may have autocrine and paracrine effects (40). Previous work has shown that the synergistic action of hypothalamic GH-releasing hormone (GHRH) and ghrelin plays an important role in GH secretion from the pituitary gland (41, 42). Expression of growth hormone secretagogue receptor (GHS-R) mRNA in normal human pituitary, as well as in various pituitary tumours, has been demonstrated (40). Ghrelin modulates GH secretion by binding to GHS-R1A (43), allowing it to cross the blood-brain barrier (44). Earlier studies have shown that the effects of ghrelin on GH release in vivo (43) are significantly more potent than those in vitro (1) and more pronounced in humans than in animals (43). Nanomolar doses of centrally administered ghrelin significantly increase circulating serum GH levels by 15% (*Figure 3B*) (27) and reduce thyroid-stimulating hormone (TSH) by about 14% (31) compared to corresponding control values. It is hypothesised that by modulating the GH-insulin growth factor axis, desacyl ghrelin may induce GH secretion (45). An earlier study showed that ghrelin stimulates GH release in vitro but has no significant effect on TSH, prolactin, ACTH, luteinising hormone (LH), or follicle-stimulating hormone (FSH) release (40).

Morphometric characteristics after ghrelin treatment

The body weight of control and ghrelin-treated rats is summarised in *Figure 4A*. It is clearly seen that body weight increased in adult rats, but this increase was not statistically significant (22, 27, 46). A substantial increase in body weight was observed after ghrelin administration in peripubertal rats (18). Previous studies have shown that ghrelin influences food intake (47), weight gain and obesity via homeostatic pathways in the brainstem (48) and hypothalamus (49). The results of studies on the effects of central administration of nanomolar doses of ghrelin on body weight, food intake, fat deposition, and lipid metabolism during aging (in peripubertal, adult, and middle-aged rats) showed that all these parameters were significantly increased compared to controls (18). The increase in body weight is most pronounced in the youngest rats and decreases with age, indicating that these parameters are age-dependent (46, 50). Greater sensitivity to the stimulatory effects of adipogenesis, HPA axis activity, and lipid metabolites has been observed in middle-aged rats after ghrelin treatment (18, 35)

Morphometric characteristics after centrally administered ghrelin on absolute and relative pituitary weight, absolute volume and volume density of ACTH, GH, FSH and LH cells are shown in *Figure 4B–E*. Absolute and relative pituitary weights were significantly increased in ghrelin-treated animals by 58% and 41%, respectively, compared with the control group (*Figure 4B, C*) (22, 27).

The absolute weight of the pituitary gland in control FR rats was statistically significantly lower than in control rats with a standard diet (26). In HF control animals, absolute pituitary weight was 35.9% significantly higher compared to NF control rats. However, ghrelin administration did not cause significant changes in absolute or relative pituitary weight in any of the treated groups compared to the corresponding control (26).

The analysed stereological parameters (volume and volume density) for rat pituitary cells are shown in *Figure 4D, E*. It can be observed that in adult rats treated with ghrelin, the volume of both ACTH cells and GH cells statistically significantly increased by 17%, and that of LH cells by 7% compared to the corresponding control (*Figure 4D*) (22, 27, 32), while the volume of FSH cells remained unchanged (32).

The volume density of ACTH and GH cells was significantly increased by 13% and 19%, respectively, in ghrelin-treated rats, and in LH cells this parameter was significantly decreased by 38.9% compared to the control group (*Figure 4E*) (22, 27, 32). The volume density of FSH cells was slightly lower than in the control group (32).

Stereological analysis showed that repeated nanomolar doses of ghrelin statistically significantly increased the volume of ACTH cells in NF, HF, and FR rats compared with their corresponding controls. The volume density of these cells in NF, HF, and FR rats was significantly altered only compared with NF controls (26).

Potential therapeutic capacities of ghrelin

Appetite regulation is very complex (stimulation/inhibition) and includes, in addition to ghrelin, gut peptides, insulin, leptin and the arcuate nucleus of the hypothalamus (51). Decreased or lost appetite and/or food intake in older adults, described as »anorexia of aging«, was first named and described

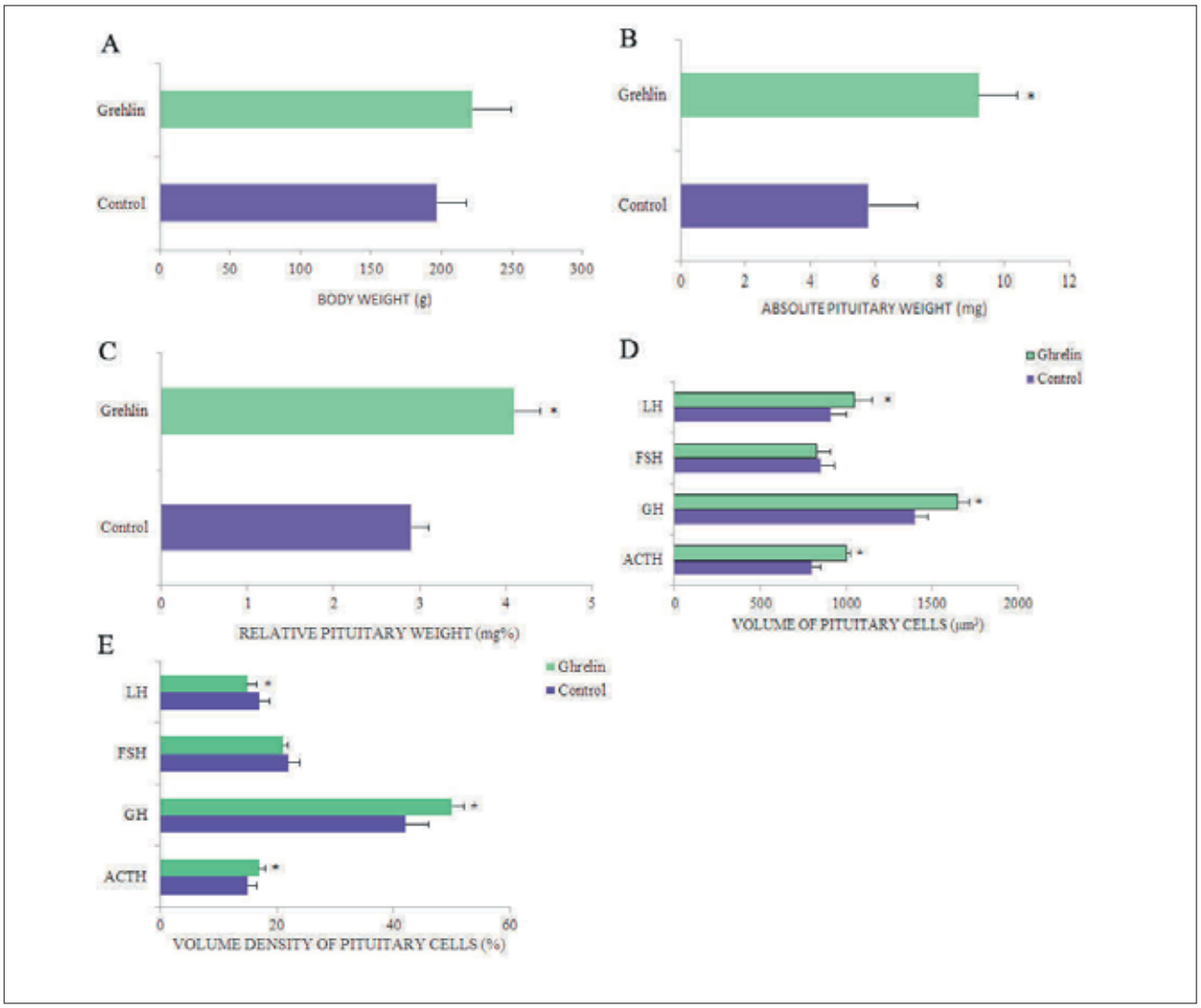

Figure 4 Graphic representation of morphometric parameters: A – body weight (g), absolute – B (mg) and C– relative (mg%) pituitary weights, D – volume of immunopositive ACTH, GH, FSH and LH cells (μm^3) and E – volume density (%) of immunopositive ACTH, GH, FSH and LH cells in adult control and ghrelin treated rats. ACTH-corticotropic cells, GH-somatotropic cells, follicle-stimulating FSH-producing cells, and luteinizing-LH-producing cells. The values are expressed as means ± SD; *$p<0.05$ vs. control; n=10.

by Morley et al. (52). This condition in older adults is associated with chronic diseases, neurodegenerative conditions, and the use of numerous medications. It has recently been recognised as a geriatric syndrome (20). Loss of appetite and weight in older people may be associated with worsening mental health, including depression and cognitive impairment (53). It is also believed that dysregulation of the release, action, and/or resistance of peripheral hormones contributes to »anorexia of aging« (54). Inhibition of appetite is also aided by satiety hormones, including leptin, glucagon-like peptide-1, peptide YY, and cholecystokinin, through the involvement of the hypothalamus (10). It is essential to emphasise that healthy longevity should be a priority for every country; therefore, the timely identification of »anorexia of aging« during preventive health screenings is crucial. Appetite plays a key role in managing the risks associated with aging, to avoid the occurrence of sarcopenia, cachexia, frailty, and disability (55). Most studies on acylated ghrelin focus on its physiological and pathophysiological effects in the body (8, 21, 56). In recent years, ghrelin has been shown to play a significant biological role in autophagy, apoptosis, and appetite regulation (8). In the gastrointestinal tract, autophagy plays a crucial role in the pathogenesis of Crohn's disease, Helicobacter pylori infection, chronic gastritis, various infectious diseases, and gastrointestinal tract cancers (56). Studies by Ezquerro et al. (57) have demonstrated that ghrelin promotes autophagy by activating adenosine monophosphate-activated protein kinase, thereby influencing glucose and lipid metabolism. Ghrelin, as an anti-inflammatory peptide, acts in inflammatory conditions to prevent cell damage and

reduce autophagic flux (58). Ghrelin analogues have the potential to be used in the treatment of disorders caused by growth hormone deficiency (8). During development and growth, apoptosis, a regulated process of cell death, plays a crucial role (59). Depending on the cell type, ghrelin's influence varies, and its role in OE-19 cells of the gastrointestinal tract is particularly noticeable (60).

In patients with sepsis, ghrelin inhibits oxidative stress. It reduces the release of the pro-inflammatory factor high-mobility group box 1 (HMGB1) (61), activates the vagus nerve, and thereby improves the function of the gastrointestinal mucosa (8).

In patients with gastric cancer, a meta-analysis showed significantly lower circulating ghrelin levels compared to healthy individuals (62). Further research in this field is needed, as there are contradictory results from studies regarding serum ghrelin levels in healthy individuals and those with cancer (63).

Endogenous and exogenous ghrelin have potent beneficial effects on heart failure and hypertrophy, myocardial infarction, as well as on minor arrhythmias and pulmonary hypertension (64). These effects occur as a result of ghrelin's direct action on cardiac cells as well as modulation of the autonomic nervous system. Ghrelin thus represents a promising new treatment for heart disease compared to other drugs, as it is an endogenous hormone (65).

Conclusion

The multifunctionality of ghrelin's action and the complexity of regulating the hypothalamic-pituitary axis and target tissues throughout the body are crucial for understanding the diseases and health issues caused by circulating ghrelin deficiency. This review showed that central administration of nanomolar doses of ghrelin in rats modulates the immunohistomorphometric and hormonal characteristics of pituitary hormone-producing cells. The changes are particularly significant in the volumes, volume densities, and hormone levels of corticotropes and somatotropes compared with controls. The involvement of ghrelin in apoptosis, autophagy, gastrointestinal disorders, colon and gastric cancer, postoperative recovery, and cardiovascular diseases suggests that it is a hormone with multiple effects on health, making it suitable for therapeutic purposes. Ghrelin and its analogues may play a key role in improving postoperative recovery. However, additional research in this field is necessary to ensure patient safety during its use.

Acknowledgements. The authors would like to thank the Ministry of Education, Science, and Technological Development of the Republic of Serbia (Grant No. 451-03-137/2025-03/200113) for financial support.

Conflict of interest statement

All the authors declare that they have no conflict of interest in this work.

References

1. Kojima M, Hosoda H, Date Y, Nakazato M, Matsuo H, Kangawa K. Ghrelin is a growth-hormone-releasing acylated peptide from stomach. Nature 1999; 402: 656–60. DOI: 10.1038/45230
2. Akalu Y, Molla MD, Dessie G, Ayelign B. Physiological effect of ghrelin on body systems Int J Endocrinol 2020; 2020: 1385138. DOI: 10.1155/2020/1385138
3. Hong SH, Choi KM. Gut hormones and appetite regulation. Curr Opin Endocrinol Diabetes Obes 2024; 31(3): 115–21. DOI: 10.1097/MED.0000000000000859
4. Tack J, Verbeure W, Mori H, Schol J, Van den Houte K, Huang IH, Balsiger L, Broeders B, Colomier E, Scarpellini E, Carbone F. The gastrointestinal tract in hunger and satiety signalling. United European Gastroenterol J 2021; 9(6): 727–34. DOI: 10.1002/ueg2.12097
5. Sato T, Nakamura Y, Shiimura, Ohgusu H, Kangawa K, Kojima M. Structure, regulation and function of ghrelin. J Biochem 2012; 151: 119–28. DOI: 10.1093/jb/mvr134
6. Seim I, Collet C, Herington AC, Chopin LK. Revised genomic structure of the human ghrelin gene and identification of novel exons, alternative splice variants and natural antisense transcripts. BMC Genom 2007; 8: 298. DOI: 10.1186/1471-2164-8-298
7. Du GM, Luo BP, Hu ZH, Wu JG, Yan WM, Han ZQ, Zhang YH, Liu MJ. The effect of ghrelin O-acyltransferase inhibitor on gastric H+-K+-ATPase activity and GOAT/ghrelin system in gastric mucosal cells in vitro. Gen Comp Endocrinol 2018; 267: 167–71. DOI: 10.1016/j.ygcen.2018.06.020
8. Wu W, Zhu L, Dou Z, Hou Q, Wang S, Yuan Z, Li B. Ghrelin in Focus: Dissecting its critical roles in gastrointestinal pathologies and therapies. Curr Issues Mol Biol 2024; 46(1): 948–64. DOI: 10.3390/cimb46010061
9. Grönberg M, Tsolakis AV, Magnusson L, Janson ET, Saras J. Distribution of obestatin and ghrelin in human tissues: immunoreactive cells in the gastrointestinal tract, pancreas, and mammary glands. J Histochem Cytochem 2008; 56(9): 793–801. DOI: 10.1369/jhc.2008.951145
10. Delporte C. Structure and physiological actions of ghrelin. Scientifica 2013; 518909. DOI: 10.1155/2013/518909

11. Nishi Y, Yoh J, Hiejima H, Kojima M. Structures and molecular forms of the ghrelin-family peptides. Peptides 2011; 32(11): 2175–82. DOI: 10.1016/j.peptides.2011.07.024

12. Bukhari SNA. An insight into the multifunctional role of ghrelin and structure activity relationship studies of ghrelin receptor ligands with clinical trials. Eur J Med Chem 2022; 235: 114308. DOI: 10.1016/j.ejmech.2022.114308

13. Nampoothiri VM. Ghrelin and its role in animals. International Journal of Veterinary Sciences and Animal Husbandry 2021; 6(1): 19–22. DOI: 10.22271/veterinary.2021

14. Otero M, Nogueiras R, Lago F, Dieguez C, Gomez-Reino JJ, Gualillo O. Chronic inflammation modulates ghrelin levels in humans and rats. Rheumatology (Oxford) 2004; 43(3): 306–10. DOI: 10.1093/rheumatology/keh055

15. Dornonville de la Cour C, Björkqvist M, Sandvik AK, Bakke I, Zhao CM, Chen D, Håkanson R. A-like cells in the rat stomach contain ghrelin and do not operate under gastrin control. Regul Pept 2001; 99(2–3): 141–50. DOI: 10.1016/s0167-0115(01)00243-9

16. Korbonits M, Goldstone AP, Gueorguiev M, Grossman AB. Ghrelin hormone with multiple functions. Front Neuroendocrinol 2004; 25: 27–68. DOI: 10.1016/j.yfrne.2004.03.002

17. Skoracka K, Hryhorowicz S, Schulz P, Zawada A, Ratajczak-Pawłowska AE, Rychter AM, Słomski R, Dobrowolska A, Krela-Kaźmierczak I. The role of leptin and ghrelin in the regulation of appetite in obesity. Peptides 2025; 186: 171367. DOI: 10.1016/j.peptides.2025.171367

18. Nešić D, Stevanović D, Stanković S, Milošević V, Trajković V, Starčević V, Severs W, Age-dependent modulation of central ghrelin effects on food intake and lipid metabolism in rats. Eur J Pharmacol 2013; 710: 85–91. DOI: 10.1016/j.ejphar.2013.03.052

19. Chapman IM, MacIntosh CG, Morley JE, Horowitz M. The anorexia of ageing. Biogerontology 2002; 3(1–2): 67–71. DOI: 10.1023/a:1015211530695

20. Landi F, Calvani R, Tosato M, Martone AM, Ortolani E, Savera G, Sisto A, Marzetti E. Anorexia of Aging: Risk Factors, Consequences, and Potential Treatments. Nutrients 2016; 8(2): 69. DOI: 10.3390/nu8020069

21. Yanagi S, Sato T, Kangawa K, Nakazato M. The Homeostatic force of ghrelin. Cell Metab 2018; 27(4): 786–804. DOI: 10.1016/j.cmet.2018.02.008

22. Stevanović D, Milosević V, Starčević VP, Severs WB. The effect of centrally administered ghrelin on pituitary ACTH cells and circulating ACTH and corticosterone in rats. Life Sci 2007; 80(9): 867–72. DOI: 10.1016/j.lfs.2006.11.018

23. Čukuranović-Kokoris J, Ajdžanović V, Pendovski L, Ristić N, Milošević V, Dovenska M, et al. The effects of long-term exposure to moderate heat on rat pituitary ACTH cells: histological and hormonal study. Acta Vet 2022a; 72(1): 1–15. DOI: 10.2478/acve-2022-0001

24. Pavlović M, Jovanović I, Ugrenović S, Stojanović V, Živković V, Kundalić B, et al; Human anterior pituitary's ACTH cells during the aging process: immunohistochemic and morphometric study. Anat Sci Int 2021; 96(2): 250–7. DOI: 10.1007/s12565-020-00583-7

25. Čukuranović-Kokoris J, Kundalić B, Pavlović M, Ugrenović S. Pituitary cells in man during aging: an immunohistological and morphometric study. J Med Biochem 2025a; 44(2): 203–10. DOI: 10.5937/jomb0-54605

26. Milošević V, Ajdžanović V, Nešić D, Starčević V, Filipović B, Rakočević R, et al. Central ghrelin treatment stimulates ACTH cells in normal-fed, food-restricted and high-fed rats: An immunohistomorphometric and hormonal study. Acta Histochem 2013; 115: 858–64. DOI: 10.1016/j.acthis.2013.04.003

27. Stevanović D, Milošević V, Nešić D, Ajdžanović V, Starčević V, Severs W. Central effects of ghrelin on serum growth hormone and morphology of pituitary somatotropes in rats. Exp Biol Med (Maywood) 2006; 231(10): 1610–5. DOI: 10.1177/153537020623101005

28. Čukuranović-Kokoris J, Đorđević M, Jovanović I, Kundalić B, Pavlović M, Graovac I, et al: Morphometric analysis of somatotropic and folliculostellate cells of human anterior pituitary during ageing. Srp Arh Celok Lek 2022b; 50(5–6): 274–81. DOI: 10.2298/SARH211214044C

29. Čukuranović Kokoris J, Dovenska M, Parapid B, Pendovski L, Nikolovski M, Kundalić B, et al. Immunohistomorphometric response of pituitary growth hormone producing cells in rats to prolonged exposure to moderately elevated ambient temperature. Srp Arh Celok Lek 2025b; 153(5–6): 243–7. DOI: 10.2298/SARH250515041C

30. Čukuranović-Kokoris J, Marković-Filipović J, Đorđević M, Kundalić B, Stojanović V, Trandafilović M, et al. Correlation analysis of pituitary lutheinizing and somatotropic cells in male cadavers during aging. Acta Medica Medianae 2024; 63(1): 90–6. DOI: 10.5633/amm.2024.0110

31. Šošić-Jurjević B, Stevanović D, Milošević V, Sekulić M, Starčević V. Central ghrelin affects pituitary-thyroid axis: histomorphological and hormonal study in rats. Neuroendocrinology 2009; 89: 327–36. DOI: 10.1159/000188603

32. Ristić N, Stevanović D, Nešić D, Ajdžanović V, Rakočević R, Jarić I, et al. Diet-induced obesity and ghrelin effects on pituitary gonadotrophs: immunohistomorphometric study in male rats. Cell J 2016; 17: 709–11. DOI: 10.22074/cellj.2016.3843Ć

33. Čukuranović-Kokoris J, Jovanović I, Pantović V, Krstić M, Stanojković M, Milošević V, et al. Morphometric analysis of the folliculostellate cells and luteinising hormone gonadotropic cells of the anterior pituitary of the men during the aging process. Tissue and Cell 2017; 49(1): 78–85. DOI: 10.1016/j.tice.2016.11.006

34. Čukuranović-Kokoris J, Jovanović I, Ugrenović S, Stojanović V, Pavlović M, Kundali B, et al. Immuno histochemical and morphometric study of adenohypophyseal gonadotropic cells in male cadavers of different ages. Acta Medica Medianae 2020; 59(4): 49–61. DOI: 10.5633/amm.2020.0407

35. MilosevicV, Stevanovic DM, Nesic DM, Sosic-Jurjevic BT, Ajdzanovic VZ, Starcevic VP, et al. Central effects of ghre-

lin on the adrenal cortex: a morphological and hormonal study. Gen Physiol Biophys 2010; 29(2): 194–202. DOI: 10.4149/gpb_2010_02_194

36. Gillies GE, Linton EA, Lowry PJ. Corticotropin releasing activity of the new CRF is potentiated several times by vasopressin. Nature 1982; 299(5881): 355–7. DOI: 10.1038/299355a0

37. Wren AM, Small CJ, Fribbens CV, Neary NM, Ward HL, Seal LJ, Ghatei MA, Bloom SR. The hypothalamic mechanisms of the hypophysiotropic action of ghrelin. Neuroendocrinology 2002; 76(5): 316–24. DOI: 10.1159/000066629

38. Azzam I, Gilad S, Limor R, Stern N, Greenman Y. Ghrelin stimulation by hypothalamic pituitary adrenal axis activation depends on increasing cortisol levels. Endocrine Connections 2017; 6: 847–55. DOI: 10.1530/EC-17-0212

39. Rucinski M, Ziolkowska A, Tyczewska M, Malendowicz LK. Expression of prepro ghrelin and related receptor genes in the rat adrenal gland and evidences that ghrelin exerts a potent stimulating effect on corticosterone secretion. Peptides 2009; 30(8): 1448–55. DOI: 10.1016/j.peptides.2009.04.016

40. Korbonits M, Kojima M, Kangawa K, Grossman AB. Presence of ghrelin in normal and adenomatous human pituitary. Endocrine 2001; 14(1): 101–4. DOI: 10.1385/ENDO:14:1:101

41. Popovic V, Miljic D, Micic D, Damjanovic S, Arvat E, Ghigo E, et al. Ghrelin main action on the regulation of growth hormone release is exerted at hypothalamic level. J Clin Endocrinol Metab 2003; 88(7): 3450–3. DOI: 10.1210/jc.2003-030211

42. Malagón MM, Luque RM, Ruiz-Guerrero E, Rodríguez-Pacheco F, García-Navarro S, Casanueva FF, et al. Intracellular signaling mechanisms mediating ghrelin-stimulated growth hormone release in somatotropes. Endocrinology 2003; 144(12): 5372–80. DOI: 10.1210/en.2003-0723

43. Muccioli G, Papotti M, Locatelli V, Ghigo E, Deghenghi R. Binding of 125I-labeled ghrelin to membranes from human hypothalamus and pituitary gland. Journal of Endocrinological Investigation 2001; 24(3): RC7–9. DOI: 10.1007/BF03343831

44. Uriarte M, De Francesco PN, Fernández G, Castrogiovanni D, D'Arcangelo M, Imbernon M, et al. Circulating ghrelin crosses the blood-cerebrospinal fluid barrier via growth hormone secretagogue receptor dependent and independent mechanisms. Mol Cell Endocrinol 2021; 538: 111449. DOI: 10.1016/j.mce.2021.111449.

45. Ariyasu H, Takaya K, Iwakura H, Hosoda H, Akamizu T, Arai Y, Kangawa K, Nakao K. Transgenic mice overexpressing des-acyl ghrelin show small phenotype. Endocrinology 2005; 146(1): 355–64. DOI: 10.1210/en.2004-0629

46. Stevanovic D, Nesic D, Milosevic V, Starcevic V, Severs WB. Consum- matory behavior and metabolic indicators after central ghrelin injections in rats. Regul Pept 2008; 147(1–3): 52–9. DOI: 10.1016/j.regpep.2008.01.003

47. Wren AM, Small CJ, Fribbens CV, Neary NM, Ward HL, Seal LJ, et al. The hypothalamic mechanisms of the hypophysiotropic action of ghrelin. Neuroendocrinology 2002; 76(5): 316–24. DOI: 10.1159/000066629

48. Faulconbridge LF, Cummings DE, Kaplan JM, Grill HJ. Hyperphagic effects of brainstem ghrelin administration. Diabetes 2003; 52(9): 2260 5. DOI: 10.2337/diabetes.52.9.2260

49. Hewson AK, Dickson SL. Systemic administration of ghrelin induces Fos and Egr 1 proteins in the hypothalamic arcuate nucleus of fasted and fed rats. J Neuroendocrinol 2000; 12(11): 10479. DOI: 10.1046/j.1365-2826.2000.00584.x

50. Nesić DM, Stevanović DM, Ille T, Petricević S, Masirević-Drasković G, Starčević VP. Centrally applied ghrelin affects feeding dynamics in male rats. J Physiol Pharmacol 2008; 59(3): 489–500.

51. Morley JE. Anorexia of ageing: a key component in the pathogenesis of both sarcopenia and cachexia. J Cachexia Sarcopenia Muscle 2017; 8(4): 523–6. DOI: 10.1002/jcsm.12192

52. Morley JE, Silver AJ. Anorexia in the elderly. Neurobiol Aging 1988; 9(1): 9–16. DOI: 10.1016/s0197-4580(88)80004-6

53. Aprahamian I, Romanini CV, Lima NA, An VN, Aguirre BN, Galdeano JR. et al. The concept of anorexia of aging in late life depression: A cross-sectional analysis of a cohort study. Arch Gerontol Geriatr 2021; 95: 104410. DOI: 10.1016/j.archger.2021.104410

54. Merchant RA, Morley JE. Rapid geriatric assessment in primary care practice. J Nutr Health Aging 2021; 25(9): 1034–6. DOI: 10.1007/s12603-021-1681-8

55. Merchant RA, Woo J, Morley JE. Anorexia of ageing: Pathway to frailty and sarcopenia. J Nutr Health Aging 2022; 26(1): 3–5. DOI: 10.1007/s12603-021-1703-6

56. Wang T, Liu K, Wen L, Yang Y, Yin X, Liu K, et al. Autophagy and gastrointestinal diseases. Adv Exp Med Biol 2020; 1207: 529–56. DOI: 10.1007/978-981-15-4272-5_38

57. Ezquerro S, Frühbeck G, Rodríguez A. Ghrelin and autophagy. Curr Opin Clin Nutr Metab Care 2017; 20(5): 402–8. DOI: 10.1097/MCO.0000000000000390

58. TheinW, Po WW, Choi WS, Sohn UD. Autophagy and digestive disorders: Advances in understanding and therapeutic approaches. Biomol Ther 2021; 29(4): 353–64. DOI: 10.4062/biomolther.2021.086

59. Bertheloo, D, Latz E, Franklin BS. Necroptosis, pyroptosis and apoptosis: An intricate game of cell death. Cell Mol Immunol 2021; 18(5): 1106–21. DOI: 10.1038/s41423-020-00630-3

60. Konturek PC, Burnat G, Rau T, Hahn EG, Konturek S. Effect of adiponectin and ghrelin on apoptosis of Barrett adenocarcinoma cell line. Dig Dis Sci 2008; 53(3): 597–605. DOI: 10.1007/s10620-007-9922-1

61. Wu JN, Wu W, Jiang RL, Zhu MF, Lei S, Lu B. Effect of electro-acupuncture at zusanli (ST36) on the expression of ghrelin and HMGB1 in the small intestine of sepsis

rats. Zhongguo Zhong Xi Yi Jie He Za Zhi 2014; 34(9): 1113–7.

62. Wang Y, Zhang C, Yu J, Zhang Q, Wang Y, Xia Y, Dong J. Circulating ghrelin levels in patients with gastric cancer: A systematic review and meta-analysis. Front Oncol 2023; 13: 1255112. DOI: 10.3389/fonc.2023.1255112

63. Kasprzak A. Role of the ghrelin system in colorectal cancer. Int J Mol Sci 2022; 23(10); 5380. DOI: 10.3390/ijms23105380

64. Zhang CJ, Bidlingmaier M, Altaye M, Page LC, D'Alessio D, Tschöp MH, et al. Acute administration of acyl, but not desacyl ghrelin, decreases blood pressure in healthy humans. Eur J Endocrinol 2017; 176(2): 123–32. DOI: 10.1530/EJE-16-0789

65. Tokudome T, Otani K, Miyazato M, Kangawa K. Ghrelin and the heart. Peptides 2019; 111: 42–6. DOI: 10.1016/j.peptides.2018.05.006

Received: September 27, 2025

Accepted: October 29, 2025